

Crescentic IgA nephropathy with preserved renal function

Ricardo A. Macau¹, Joana R. Silva¹, Hélder Coelho², Pedro Bravo¹, Fernanda Carvalho³, Aura Ramos¹

¹ Hospital Garcia de Orta, Nephrology Department, Almada

² Hospital Garcia de Orta, Anatomic Pathology Department, Almada

³ Hospital Curry Cabral, Nephrology Department, Lisbon

Received for publication: Nov 2, 2017

Accepted in revised form: Dec 20, 2017

ABSTRACT

Crescentic glomerulonephritis is a severe form of glomerular inflammation. IgA nephropathy (IgAN) is the most common primary glomerulonephritis and rarely presents as crescentic glomerulonephritis with rapidly progressive glomerulonephritis. Treatment of IgAN includes renin-angiotensin system blockade and immunosuppression in select cases with persistent proteinuria and/or renal failure, which are also indications for biopsy. Prognosis markers guide treatment and crescents are recognized as an indication of powerful immunosuppression as they are associated with rapid decline of renal function. We describe a case of crescentic IgA nephropathy with preserved renal function that was associated with several episodes of severe tonsillitis. Renin-angiotensin system blockade and corticosteroids were used and renal function remains stable. To our knowledge, this is the third case described in the literature of a patient with crescents and IgA glomerular deposition but with preserved renal function. A more benign aspect of crescents and association with tonsillitis episodes may explain a more favorable prognosis.

Key-words: Crescentic Glomerulonephritis, Hematuria, IgA Nephropathy, Immunosuppression

INTRODUCTION

Crescentic glomerulonephritis (GN) is histologically recognized as the most severe form of glomerular inflammation, including extra-capillary cells, both proliferating parietal epithelial cells and infiltrating leucocytes, and plasma proteins within Bowman's space. Crescents are present in at least 50% of the glomeruli, and necrosis of the glomerular tuft and periglomerular inflammation are often associated¹⁻⁴. Idiopathic or primary crescentic GN (CGN) are classified in different types, based on the pattern of immunoglobulins or immune-complex deposition³. CGN is usually correlated with rapidly progressive glomerulonephritis (RPGN)¹⁻⁴ and a higher extension of crescents (circumferential) is associated with a poorer prognosis⁴.

IgAN is the most common primary GN and is known to be an important cause of end stage renal disease (ESRD). Presentation, clinical course and histology can be extremely variable, making any histological classification difficult. Henoch-Schönlein purpura is a related entity with extra-renal manifestations. Renal insufficiency and persistent proteinuria are the most common indications for kidney biopsy. Persistent microhematuria is another, after ruling out other etiologies.⁵⁻⁷ The majority of children and young adults with IgAN present with macroscopic hematuria during an upper respiratory or gastrointestinal illness^{6,7}. Older adults usually present with proteinuria, microscopic hematuria, or hypertension, sometimes in combination of renal insufficiency^{6,7}. Reversible acute renal failure (ARF) after

macroscopic hematuria associated with hematic tubular casts and acute tubular necrosis had been early described⁸. Nephrotic syndrome is uncommon in primary IgAN. Another form of presentation is crescentic IgAN usually as RPGN⁹ and sometimes is associated with ANCA¹⁰.

The pathogenesis of IgAN is not fully understood. The disease is characterized by IgA1-immune deposits, and complement factors and neutrophil infiltration. GalactoseG-deficient-IgA1 may play a role by activating neutrophils via the IgA Fc receptor¹¹⁻¹³. Treatment of IgAN includes renin-angiotensin system (RAS) blockers and corticosteroids in selected cases, associated with other powerful but potentially harmful immunosuppressors¹⁴⁻¹⁶. Omega 3 fatty acids have also been tried with no clear benefit^{17,18}. The Kidney Disease: Improving Global Outcomes (KDIGO) guidelines recommend the use of corticosteroids for IgAN patients with persistent proteinuria ≥ 1 g/day under RAS blockers treatment and presenting a glomerular filtration rate (GFR) >50 mL/min/1.73 m²¹⁸. Nevertheless, results from the STOP-IgAN clinical trial did not show a significant benefit related with the addition of immunosuppression¹⁹. In patients with frequent episodes of macroscopic hematuria during tonsillitis and IgAN, tonsillectomy and corticosteroids have been tried²⁰⁻²². Previous studies assessed possible factors associated with IgAN progression¹⁶. The initial study did not show any association between crescents in IgAN biopsies and IgAN prognosis in Oxford Classification²³, but two subsequent studies suggested an association^{24,25}. In particular, Trimarchi et al. showed that IgAN prognosis is correlated with crescent presence and extension²⁴. Mesangial hypercellularity (M), endocapillary cellularity (E), segmental sclerosis (S), interstitial fibrosis/tubular atrophy (T), and crescent (C) lesions predict clinical outcome and biopsy reporting of IgAN should provide a MEST-C score²⁴.

As abovementioned, crescentic IgAN patients usually present as RPGN. Immunosuppressive regimens with cyclophosphamide, rituximab, and mycophenolate mofetil have been recognized as efficacious in preserving renal function^{14-19,26}. However, some patients may present CGN without significant renal failure¹. One patient with HSP had been reported with CGN and preserved renal function¹. There is also a case report on a patient with crescentic IgAN, nephrotic proteinuria and only mild deterioration of renal function²⁷. We describe a case of a crescentic IgAN without significant renal failure.

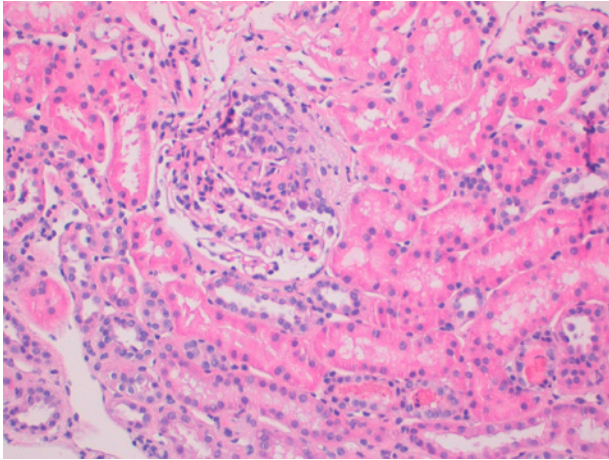
■ CASE REPORT

A 28-year-old man presented 2 years previously with macroscopic hematuria during a tonsillitis episode and microscopic hematuria in between. Serum Creatinine (SCr) at first evaluation was 0.8 mg/dL and blood pressure (BP) was 80/40 mmHg. Microscopic hematuria was present between episodes and proteinuria was 300 mg (per 24h). Past medical history included asthma and atopy. His mother had been diagnosed with non-specified nephritis in her childhood. A presumptive diagnosis of IgAN was made and he started RAS blockade, remaining stable. The previous year he had suffered from 4 episodes of acute tonsillitis with macroscopic hematuria and acute kidney injury (SCr maximal value 1.6 mg/dL). Some of the tonsillitis episodes were severe, including shortness of breath due to upper airway obstruction. Due to the frequency and severity of episodes, tonsillectomy was proposed. Kidney function improved after each episode, but did not fully recover. Extensive laboratory analyses were performed as an outpatient. He presented mild elevation of IgA (434 mg/dL for a reference range of 70-400 mg/dL), with other immunoglobulins and free light chains within the reference ranges. Complement was evaluated with both C3 and C4 levels normal (110 mg/dL [reference range 90–180] and 26.5 mg/dL [reference range 10–40], respectively). Antinuclear antibodies, ANCA, and anti-GBM were negative. Serologic profile of human immunodeficiency virus, hepatitis B and C were innocent, as well as serum protein electrophoresis. Anti-streptolysin-O reaction was also negative (100 IU – positive reaction >200 IU). On ultrasonography, both kidneys presented normal size and echogenicity. After the fourth episode of tonsillitis, SCr stabilized in 1.3 mg/dL with a measurement of creatinine clearance in a 24-hour urine collection (24-hr CrCl) of 85mL/min. The patient was under lisinopril 5 mg, and presented a BP of 110/70 mmHg and a proteinuria of 200mg/24h.

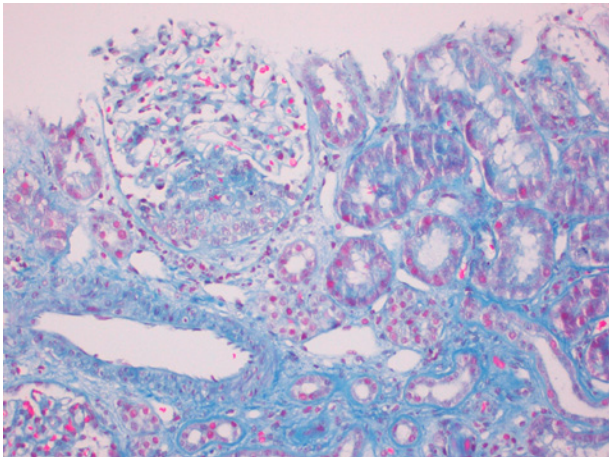
We performed a kidney biopsy 10 days after the tonsillitis episode. Biopsy specimen presented 10–13 glomeruli per slide and showed cellular crescents in 5 glomeruli (45-50%), occupying 25% of Bowman space. Neither disruption of the capsule nor necrosis of glomerular tuft were observed. There was no mesangial proliferation, endocapillary cellularity, segmental sclerosis or interstitial fibrosis, accounting for a M0-E0-S0-T0-C2 score (Figures 1 and 2). There were some hematic casts but no tubule injury was found. IgA (++) (figure 3) and C3 (+) deposits were present, confirming a diagnosis of IgAN. Due to the presence of crescents we started corticosteroids, initially with methylprednisolone

Figure 1

Kidney biopsy. Hematoxylin and eosin stain with 20x amplification. Cellular crescent occupying 25% of circumference of the glomerulus. Interstitium and tubules are preserved.

**Figure 2**

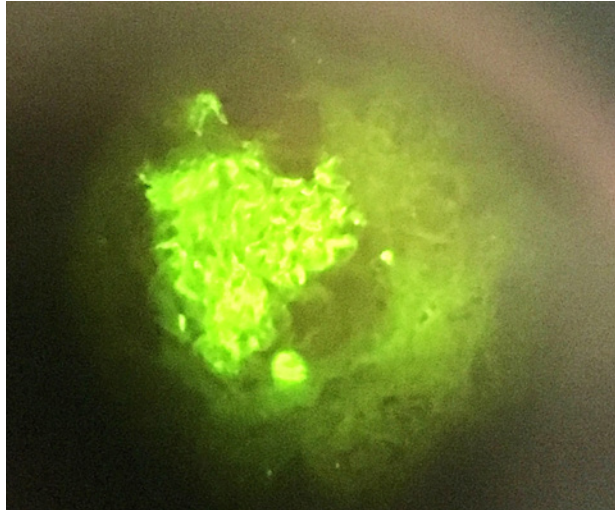
Kidney biopsy. Chromotrope aniline blue stain with 20x amplification. Cellular crescent occupying 25% of circumference of the glomerulus. Interstitium and tubules are preserved.



sodium succinate and subsequently with deflazacort 1.2mg/kg due to an allergic reaction with urticaria following the first dose of methylprednisolone). The patient completed 3 months of corticotherapy, followed by slow tapering for another 3 months. Renal function remained stable; we thus decided not to start further immunosuppressants. Semen was cryopreserved as a precautionary measure, for the event of a GFR decline, requiring immunosuppression intensification. RAS

Figure 3

Kidney biopsy. Direct immunofluorescence demonstrated diffuse mesangial IgA deposits (++)



blockade was maintained and omega 3 fatty acids were given. After 6 months, he presented a 24-hr CrCl of 86mL/min, with microscopic hematuria and 100 mg of proteinuria per 24h. Tonsillectomy was performed and an episode of macroscopic hematuria occurred during the immediate post-surgery period. Two months after surgery the patient is normotensive under RAS blockade and he presents a 24-hr CrCl of 86mL/min. SCr is 1.0mg/dL and proteinuria is within physiological values (77mg/24h) but microscopic hematuria persists (60 erythrocytes/mcL). C3 serum levels remain normal.

DISCUSSION

We presented a case of a 28-year-old male patient with frequent episodes of synfaringitic macrohematuria. This is the most common presentation of IgAN in children and young adults^{6,7}. Some of these episodes may present with reversible ARF due to intratubular obstruction⁸. However, this patient did not recover his previous values, even though there was only a slight change in GFR. He was not hypertensive but his arterial pressure profile changed (20 mmHg increase of systolic arterial pressure in two years) which was considered a risk factor for worse prognosis in IgAN^{6,7,16}. He never presented clinical significant proteinuria, even though he was treated with RAS blockers from the beginning. Intensive support treatment has been advocated as one of the most important cornerstones of IgAN^{19,24}.

As mentioned above, KDIGO guidelines suggest a 6-month course of corticosteroids for IgAN patients with persistent proteinuria ≥ 1 g/day despite 3–6 months of RAS blockers and GFR >50 mL/min/1.73 m²¹⁸. However, some studies, such as the STOP-IgAN clinical trial, did not show a better outcome of IgAN patients with the addition of immunosuppressive therapy to intensive supportive care¹⁹. Even though the clinical presentation was highly suggestive of IgAN and there was no significant hypertension or proteinuria, we decided to perform a kidney biopsy to investigate SCR oscillations and to optimize treatment. The biopsy did not show important hematic cast presence or tubule injury that would explain some degree of ARF. Signs of chronicity were also absent. Bearing in mind the implications of the sampling representation (even though the biopsy specimen had 13 glomeruli), mesangial proliferation, endocapillary cellularity segmental sclerosis, or interstitial fibrosis were absent and these all would be signs of a benign course. However, to our surprise, 45–50% of the glomeruli presented crescents (depending on the slide). These crescents were cellular and they were not circumferential, occupying only 25%, with a somehow benign aspect. Immunofluorescence showed deposits of IgA (++) and C3 (+) which are in favor of IgAN. Some studies showed that C3 hypocomplementemia and mesangial C3 deposition were independent risk factors for progression, suggesting that complement activation may play a pathogenic role in patients with IgAN²⁸, while others did not find that association²⁹. There are also some studies that indicate that serum IgA/C3 ratio may be related to CKD progression in IgAN³⁰. In our patient, C3 serum levels were persistently normal and C3 glomerular deposition was mild, which might be considered as favorable.

The presence of crescents has prognosis implications^{22–24} and most of the patients are treated with powerful immunosuppression in the presence of crescents as they usually present with RPGN^{9,20,14,18,22–24}. Some of these cases are associated with the presence of ANCA^{9,10}, which were negative in our patient. We assumed the diagnosis of primary IgAN. We have also evaluated progression risk factors: presence of crescents was a concern, but without significant proteinuria and relatively stable renal function and BP, a more benign course was also considered. The absence of chronicity signs in the biopsy was also a favorable predictor. Most of the recommendations and reports about immunosuppression in crescentic IgAN are always associated with intention to stop rapidly deteriorating kidney function^{14,16,18,19,26} which was not the case. Indications about when to perform renal biopsy in the

suspicion of IgAN may influence this, as most patients present proteinuria or relevant decline of renal function when biopsies are made. ANCA associated crescentic IgAN are treated as ANCA vasculitis^{10,26}.

This is not the first case of CGN with near normal renal function. There were also two cases with IgA glomerular deposits described. Other etiologies described were ANCA vasculitis, systemic lupus erythematosus, and anti-glomerular basal membrane (anti-GBM) disease¹. Senegal et al. had treated their patient with prednisolone and cyclophosphamide as he presented nephrotic proteinuria and severe microscopic findings²⁷. We do not know if the patient reported by McAdoo et al. received only corticosteroids or other immunosuppressants¹. It was not evident if we could follow recommendations about treating CGN that did not behave as RPGN, and we decided to start immunosuppression with corticosteroids only bearing in mind some oscillations in GFR and maintaining monitoring. The more innocent aspect of the crescents in the biopsy (exclusively cellular and occupying only 25% of the glomerulus) might explain the benign course.

RAS blockade seems to be consensual in terms of utility in preventing disease progression^{14,18,19,26} and it was used in this patient since the beginning. The use of omega 3 acids has been decided even though the results are controversial regarding its efficacy^{17,18}. Tonsillectomy is not recommended for treating IgAN even though it has been used with or without steroids with ambiguous results^{20,26,31,32}. We decided (in association with the ear, nose, and throat team) to refer this patient for tonsillectomy mostly because of the severity of tonsillitis episodes and frequent episodes of macrohematuria and ARF concomitantly. He did not present macroscopic hematuria after discharge from tonsillectomy but the follow-up period is still short. We hope for a reduction of ARF episodes frequency in our patient.

The recent update regarding the Oxford Classification of IgAN will have important impact in evaluation of this patients and treatment decisions. A recent cohort of 3,096 patients with IgAN assessed for the presence of crescents in biopsy and analyzed outcomes using the Oxford Classification. Cellular and/or fibrocellular crescents were seen in 36% of the samples. Among these, 61% had crescents in $<10\%$ of glomeruli, 30% had crescents in 10–25% of glomeruli, and 9% had crescents in $\geq 25\%$ of glomeruli. The presence of crescents in $>25\%$ of glomeruli was independently with worse prognosis irrespective of treatment.²⁵ As a result, these authors

Table 1

MEST-C criteria in the updated Oxford Classification of IgA Nephropathy (adapted from Markowitz [31])

Histological variable	Definition	Score
Mesangial hypercellularity	More than four mesangial cells in any mesangial area of a glomerulus	M0: <50% of glomeruli showing mesangial hypercellularity M1: >50% of glomeruli showing mesangial hypercellularity
Endocapillary hypercellularity	Hypercellularity due to an increased number of cells within glomerular capillary lumina	E0: no endocapillary hypercellularity E1: any glomeruli showing endocapillary hypercellularity
Segmental glomerulosclerosis	Adhesion or sclerosis (obliteration of capillary lumina by matrix) in part but not the whole glomerular tuft (excludes globally sclerosed glomeruli)	S0: absent S1: present in any glomeruli Podocyte hypertrophy and/or tip lesions should be specifically noted
Tubular atrophy or interstitial fibrosis	Estimated percentage of cortical area showing tubular atrophy or interstitial fibrosis, whichever is greater	T0: 0–25% of cortical area T1: 26–50% of cortical area T2: >50% of cortical area
Cellular or fibrocellular crescents	Percentage of glomeruli with cellular or fibrocellular crescents (excludes fibrous crescents)	C0: absent C1: 0–25% of glomeruli C2: ≥25% of glomeruli

proposed adding a C score to the Oxford Classification of IgAN, with C0 representing the absence of crescents, C1 defined by crescents in <25% of glomeruli, and C2 signifying crescents in ≥25% of glomeruli^{24,25}. Table 1 highlights the new MEST-C criteria for IgAN.

MEST was designed as a prognosis tool but accumulated experience has allowed understanding of some of the clinical implications of the MEST score. Regarding treatment, the risk associated with an E1 or C1 score, but not a C2 score, seems to be mitigated by the addition of immunosuppression^{24,33}. Our patient would fit into a C2 score and the use of immunosuppression might not change the clinical course. Some authors also recommend that podocyte hypertrophy and/or tip lesions should be specifically noted in S score, as they are associated with a more rapid decline of GFR but they are usually responsive to therapy²⁴. Further studies are needed in order to understand the correlation between prognosis categories, treatment applied and outcomes (with or without immunosuppression in addition to intensive supportive treatment with RAS blockade). Moreover the association between clinical presentation and MEST-C score is not yet well described.

CONCLUSION

IgAN can present crescentic GN without significant renal function deterioration. Indications for performing kidney biopsy in IgAN may contribute to the paucity of this association. IgAN treatment cornerstone is RAS blockade. Treatment of crescentic GN without RPGN is not yet defined and evaluation of progression risk

factors may help. Characteristics of crescents may influence prognosis. A vigilant attitude, focusing on RAS blockade and corticosteroids, has been successful in this patient but a tight monitoring must be performed in order to prevent progressive chronic kidney failure. MEST-C score is an important tool to guide prognosis in IgAN but further studies are needed in order to evaluate a correlation between clinical presentation, MEST-C score categories, treatment, and outcomes.

ACKNOWLEDGMENTS

Authors would like to thank Nephrology and Anatomic Pathology staff members, as well as Ear, Nose, and Throat medical staff. We would like to thank Andreia Leite for language editing and proofreading.

Disclosure of potential conflicts of interest: None declared

References

- McAdoo SP, Tanna A, Randone O, et al. Necrotizing and crescentic glomerulonephritis presenting with preserved renal function in patients with underlying multisystem autoimmune disease: a retrospective case series. *Rheumatology*. 2015;54(6):1025-32
- Jennette JC. Rapidly progressive crescentic glomerulonephritis. *Kidney Int*. 2003;63:1164-77.
- Parmar MS. Crescentic Glomerulonephritis. ed Medscape <https://emedicine.medscape.com> (accessed on October 20th 2017)
- Appel GB, Kapplian AA. Overview of the classification and treatment of rapidly progressive (crescentic) glomerulonephritis. ed UpToDate <http://www.uptodate.com/> (accessed on October 20th 2017)
- Pillebout E, Vérine J. IgA Nephropathy. *Nephrol Ther*. 2016;12(4):238-54
- Wyatt RJ, Julian B. IgA nephropathy. *NEJM* 2013;368:2402-14
- Cheung CK, Barratt J. Clinical presentation and diagnosis of IgA nephropathy. ed UpToDate <http://www.uptodate.com/> (accessed on October 20th 2017)
- Liu SL, Chan KW, Chan TM, Cheng IKP. Reversible acute renal failure in a patient with IgA nephropathy. *HKMJ*. 1995;1:351-3

9. Rojas-Rivera J, Fernández-Juárez J, Praga M. Rapidly progressive IgA nephropathy: a form of vasculitis or a complement-mediated disease? *Clin Kidney J.* 2015;8(5):477–481
10. Haas M, Jafri J, Bartosh SM, et al. ANCA-associated crescentic glomerulonephritis with mesangial IgA deposits. *Am J Kidney Dis.* 2000;36(4):709-18
11. Heineke MH, Ballering AV, Jamin A, et al. New insights in the pathogenesis of immunoglobulin a vasculitis (Henoch-Schönlein Purpura). *Autoimmun Rev.* 2017; doi: 10.1016/j.autrev.2017.10.009. [Epub ahead of print]
12. Yeo SC, Cheung CK, Barratt J, et al. New insights into the pathogenesis of IgA nephropathy. *Pediatr Nephrol.* 2017; doi: 10.1007/s00467-017-3699-z. [Epub ahead of print]
13. Kiryluk K, Novak J. The genetics and immunobiology of IgA nephropathy. *J Clin Invest.* 2014;124(6):2325-32
14. Pozzi C, Sarcina C, Ferrario F. Treatment of IgA nephropathy with renal insufficiency. *J Nephrol.* 2016;29(4):551-8
15. Kuppe C, van Roeyen C, Leuchtle KJ, et al. Investigations of glucocorticoid action in GN. *Am Soc Nephrol.* 2017;28(5):1408-20
16. Coppo R. Clinical and histological risk factors for progression of IgA nephropathy: an update in children, young and adult patients. *J Nephrol.* 2017;30(3):339-46
17. Hirahashi J. Omega-3 polyunsaturated fatty acids for the treatment of IgA nephropathy. *J Clin Med.* 2017;6(7):70
18. Kidney Disease: Improving Global Outcomes (KDIGO) Glomerulonephritis Work Group. KDIGO. Clinical Practice Guideline for Glomerulonephritis. *Kidney Inter Suppl.* 2012;2:139-274
19. Rauen, T, Eitner F, Fitzner C, et al. Intensive supportive care plus immunosuppression in IgA nephropathy (STOP-IgAN). *N Engl J Med.* 2015;373:2225-36
20. Kawamura T, Yoshimura M, Miyazaki Y, et al. A multicenter randomized controlled trial of tonsillectomy combined with steroid pulse therapy in patients with immunoglobulin A nephropathy. *Nephrol Dial Transplant.* 2014;29(8):1546-53
21. Nomura T, Makizumi Y, Yoshida T, Yamasoba T. The relationship between the efficacy of tonsillectomy and renal pathology in the patients with IgA nephropathy. *Int J Otol.* 2014; Article ID 451612
22. Maeda I, Hayashi T, Kogawa K, et al. Tonsillectomy has beneficial effects on remission and progression of IgA nephropathy independent of steroid therapy. *NDT.* 2012;27:2806-13
23. Roberts ISD, Cook ST, Troyanov S, et al. The Oxford classification of IgA nephropathy: pathology definitions, correlations, and reproducibility. *Kidney Inter.* 2009;76:546-56
24. Trimarchi H, Barratt J, Cattran DC, et al. Oxford classification of IgA nephropathy 2016: an update from the IgA Nephropathy Classification Working Group. *Kidney Int.* 2017;91(5):1014-21
25. Haas M, Verhave JC, Alpers CE, et al. A Multicenter study of the predictive Value of crescents in IgA Nephropathy. *JASN.* 2017;28(2):691-701
26. Cattran DC. Treatment and prognosis of IgA nephropathy. ed UpToDate. <http://www.uptodate.com/> (accessed on October 20th 2017)
27. Sengul E, Eyiletten T, Ozcan A, Yilmaz YA, Yenicesu. A case of crescentic IgA nephropathy treated with prednisolone and cyclophosphamide. *Hippokratia.* 2009;13(3):172-4
28. SeungSeung JK, Hyang MK, Beom JL, et al. Decreased circulating C3 levels and mesangial C3 deposition predict renal outcome in patients with IgA nephropathy. *PLoS One.* 2012;7(7): e40495
29. Yang X, Wei RB, Wang Y, et al. Decreased serum C3 levels in immunoglobulin A (IgA) nephropathy with chronic kidney disease: a propensity score matching study. *Med Sci Monit.* 2017;23:673-81
30. Zhang J, Wang C, Tang Y, et al. Serum immunoglobulin A/C3 ratio predicts progression of immunoglobulin A nephropathy. *Nephrology.* 2013;18(2):125-31
31. Markowitz G. Updated Oxford Classification of IgA nephropathy: a new MEST-C score. *Nat Rev Nephrol.* 2017; doi:10.1038/nrneph.2017.67
32. Nomura T, Makizumi Y, Yoshida T, Yamasoba T. The relationship between the efficacy of tonsillectomy and renal pathology in the patients with IgA nephropathy. *Int J Otol.* 2014; Article ID 451612
33. Maeda I, Hayashi T, Kogawa K, et al. Tonsillectomy has beneficial effects on remission and progression of IgA nephropathy independent of steroid therapy. *NDT.* 2012;27:2806-13

Correspondence to:

Ricardo Macau, MD

E-mail: ricardoandremacau@gmail.com